

A rare form of valproic acid induced encephalopathy



*K.Brindha, Post graduate(II year),
ESI-PGIMSR, Chennai*

Case summary



- Four month old female infant
- First born, at term, to II degree consanguineous parentage
- No perinatal asphyxia/ neonatal jaundice
- Thriving well
- Not attained any developmental milestones

Presenting complaints



- Acute onset of abnormal jerky movements s/o flexor myoclonic seizures - 10 days duration
- 30 - 40 episodes/day
- No fever/ trauma
- No h/o lethargy/ vomiting
- No history of recent vaccination

Examination



- Conscious, no dysmorphism
- Wt - 6.3kg (25-50thcentile), HC - 39.5cm (>3rd centile)
- Not following light, PERL, Fundus - Normal
- Not turning to sound
- Other cranial nerves - Normal
- Generalised hypertonia, hyper reflexia and extensor plantar response
- Other systems - Normal

Provisional diagnosis



Symptomatic infantile spasms

Investigations



- CBC, electrolytes, calcium, magnesium - Normal
- Thyroid function, LFT, RFT - Normal
- CT, MRI Brain - Normal
- Urine metabolic screening - Normal
- Tandem Mass Spectrometry - Normal
- Serum Copper - Normal
- Serum lactate/ pyruvate - Normal
- EEG - Burst suppression pattern with ?periodicity
- CSF lactate, pyruvate, glycine - Normal

Treatment



- Started on sodium valproate, clonazepam, pyridoxine and biotin with serial monitoring of LFT
- Two weeks later seizure frequency reduced to < 20 episodes/ day
- Valproate optimized to 30mg/ kg/ day
- ACTH started for further control of seizures

Further course



Two weeks after increasing the dose of valproate, baby developed -

- Persistent vomiting
- Increased seizure frequency (75 times/ day)
- Excessive sleepiness
- Blunted pain response
- No fever
- No signs of raised ICP

Features s/o encephalopathy

Diagnosis



Valproic acid induced encephalopathy
? Hyperammonemic
? Hepatic

Valproate was discontinued, following which there was

- Marked improvement in the sensorium
- Decrease in seizure frequency within 24 hrs and
- Cry in response to pain

Contd.



- Serum ammonia - 61mg% (11 - 32)
- LFT - Normal
- Serum valproate level - 109 ng/ dl (50 -100)

Revised diagnosis



Valproic acid induced
non hyperammonemic non hepatic
encephalopathy.

Why is this still valproate induced encephalopathy?

- Events temporally related to increase in the dose of valproic acid
- Discontinuation of valproate resulted in a dramatic improvement in sensorium and resolution of other symptoms
- Elevated serum levels of valproic acid
- Positive Naranjo probability score for adverse drug reaction

Naranjo Adverse Drug Reaction (ADR) Probability Score

S.No		Yes	No	Do not Know	Score in this case
1	Are there previous conclusive reports on this reaction?	+1	0	0	+1
2	Did the adverse event occur after the suspected drug was administered?	+2	-1	0	+2
3	Did the adverse reaction improve when the drug was discontinued or a specific antagonist was administered?	+1	0	0	+1
4	Did the adverse reaction reappear when the drug was re administered?	+2	-1	0	0
5	Are there alternative causes (other than the drug) that could have on their own caused the reaction?	+1	+2	0	+2
6	Did the reaction reappear when a placebo was given?	-1	+1	0	0
7	Was the drug detected in the blood (or other fluids) in concentrations known to be toxic?	+1	0	0	+1
8	Was the reaction more severe when the dose was increased or less severe when the dose was decreased?	+1	0	0	+1
9	Did the patient have a similar reaction to the same or similar drugs in any previous exposure?	+1	0	0	0
10	Was the adverse event confirmed by any objective evidence?	+1	0	0	+1
				Total	9

Definite - 9 or > 9

Probable - 5-8

Possible - 1-4

Doubtful - 0

Valproate encephalopathy



- Hyperammonemic encephalopathy
- Hepatic encephalopathy
- Non hyperammonemic non hepatic - very rare

Valproic acid induced encephalopathy – 19 new cases in Germany from 1994 to 2003 – A side effect associated to VPA-therapy not only in young children Seizure:
European Journal of Epilepsy
[Volume 15, Issue 6](#), Pages 443-448, September 2006

Pathogenesis?



COMPLEX....

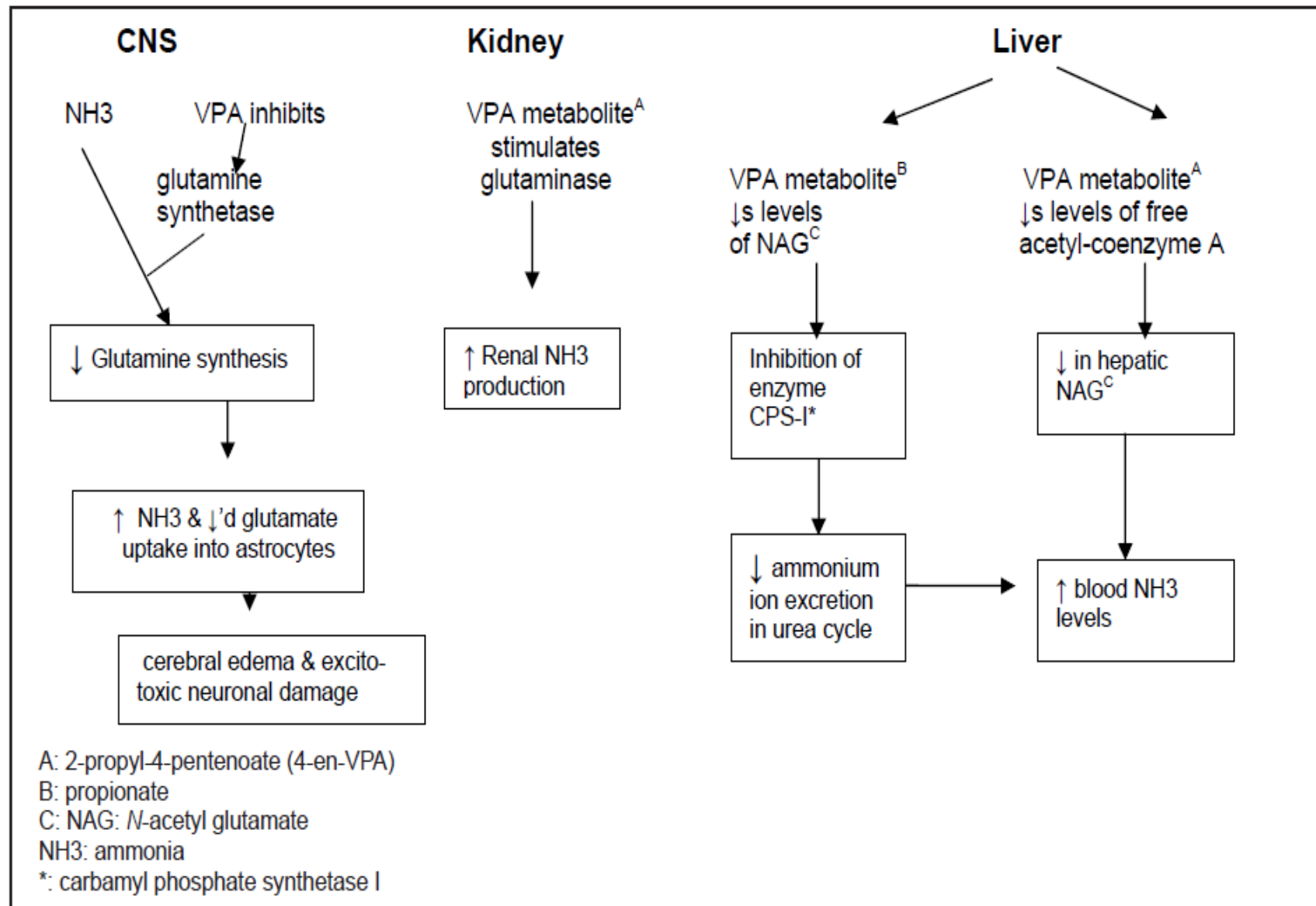
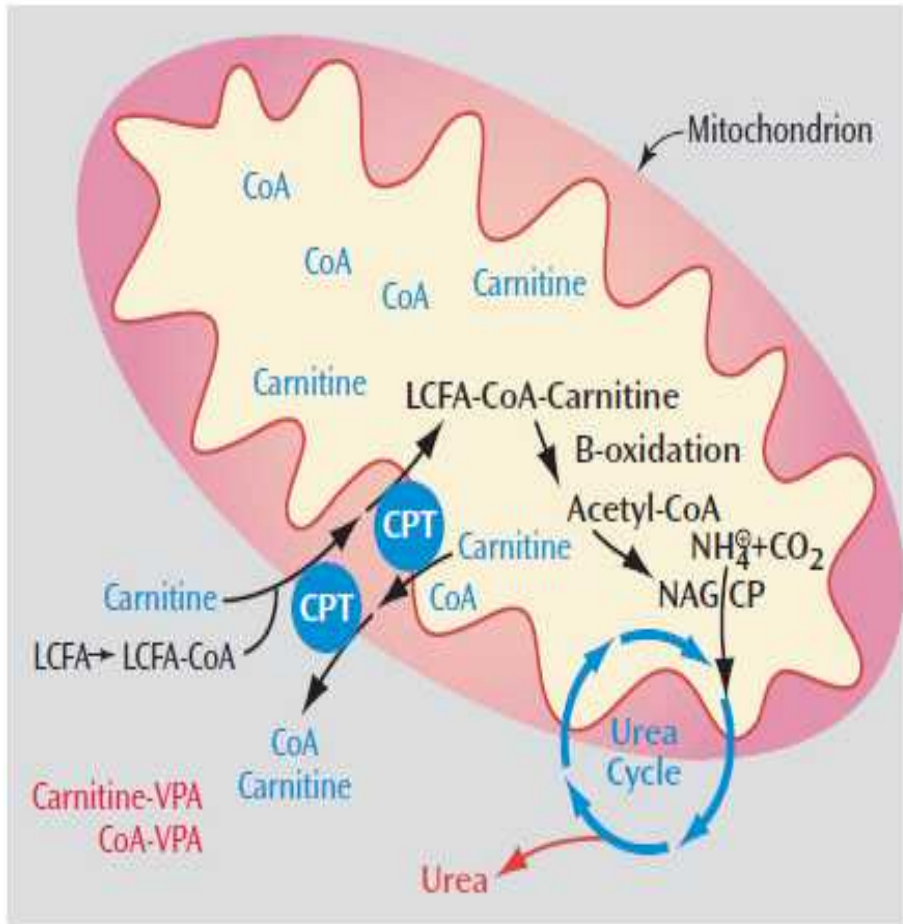


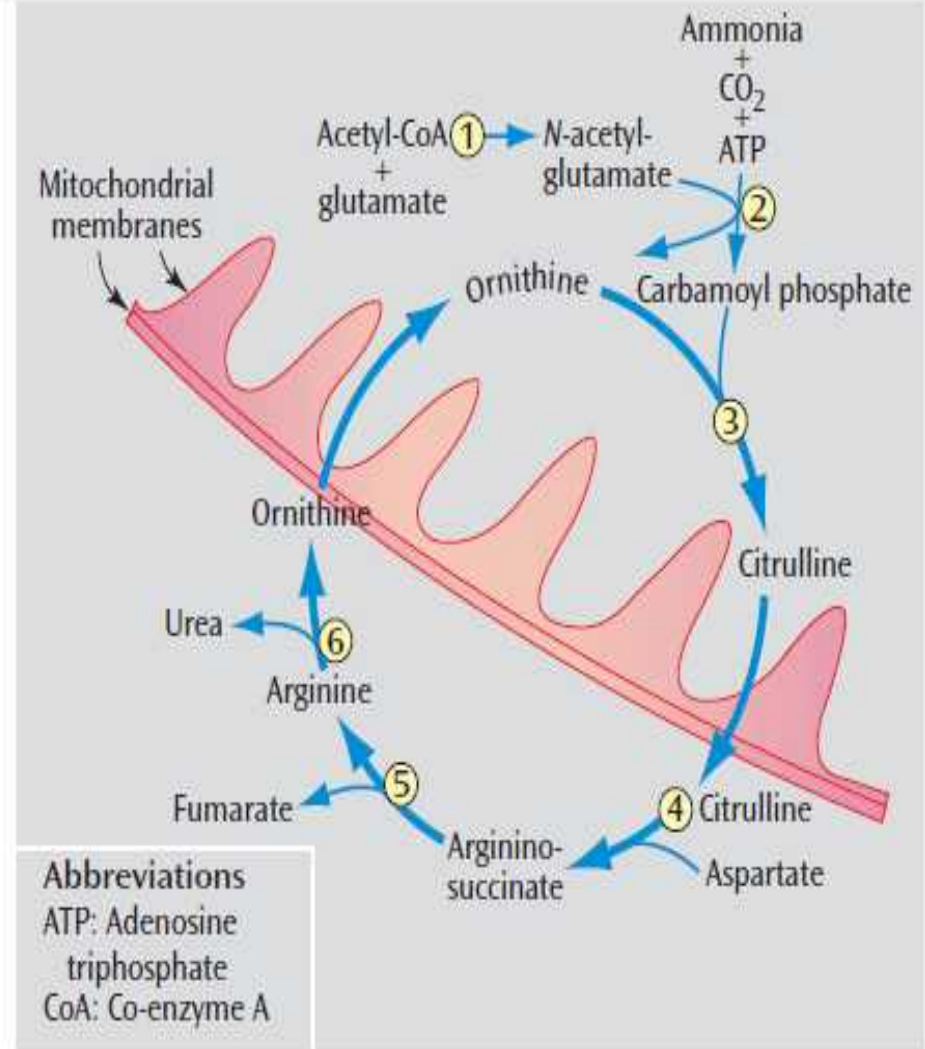
Figure 1: Schematic representation of biochemical mechanisms for VPA-induced encephalopathy



Abbreviations
 CoA: Co-enzyme A
 CP: Carbamoyl phosphate synthetase I
 CPT: Carnitine palmitoyltransferase
 LCFA: Long-chain fatty acid
 NH₄: Ammonia
 NAG: N-acetyl-glutamate
 VPA: Valproic acid

Blue: Depleted in presence of VPA

Red: Renally excreted compounds



^a N-acetyl-glutamate, which valproic acid is thought to deplete, is a required activator of carbamoyl phosphate synthetase I. Enzymes of the cycle are the following: 1) N-acetyl-glutamate synthetase, 2) carbamoyl phosphate synthetase I, 3) ornithine transcarbamylase, 4) argininosuccinate synthetase, 5) argininosuccinate lyase, and 6) arginase. Both ornithine and citrulline are transported across the mitochondrial membranes.

Risk factors for encephalopathy with VPA



- **Infancy**
- IEM - urea cycle defects, mitochondrial disorders, fatty acid oxidation defects
- Carnitine deficiency
- High dose of valproate
- Chronic therapy
- Concomitant topiramate therapy
- **?Concomitant clonazepam use**

Unique features..



- Not dose dependant
- Can occur at any time during therapy
- Does not always correlate with serum levels of the drug
- Does not have always have overt symptoms

Treatment of valproate toxicity



- Discontinuation of valproate
- Carnitine supplementation
(PO/IV 50-100mg/kg/day)
- Avoid constipation
- Protein restriction
- Adequate hydration

Valproic acid-induced encephalopathy (with a focus on carnitine treatment) Gen Hosp Psychiatry. 2012 May-Jun;34(3):290-8. Epub 2012

Feb 2. PMID: [22305367](#)

Take home message



- Valproate toxicity can occur even in the absence of deranged LFT and/ or hyperammonemia in infants
- Potentially reversible if diagnosed early, fatal if unrecognised
- If a child on valproate develops obtundation, increased seizure frequency, or vomiting - discontinue valproate pending reports

Take home message



- Naranjo ADR probability score is used to determine whether an ADR is actually due to an implicated drug or due to other factors
- It can help confirm the diagnosis in ADRs though it is not useful in poisonings

References



- Panda S, Radhakrishnan K. Two Cases of Valproate-induced Hyperammonemic Encephalopathy Without Hepatic Failure. JAPI 2004; 52
- Naranjo CA et al. A method for estimating the probability of adverse drug reactions. Clin Pharmacol Ther 1981; 30: 239245.
- Zerjav S, Stowe R. Serious Neurological Complications of Valproate Therapy, Psychopharmacology Newsletter. July/August 2007
- Reif A, Leonhard C, Mfgner R, Lesch KP, Fallgatter AJ. Encephalopathy and myoclonus triggered by valproic acid. Progress in Neuro-Psychopharmacology & Biological Psychiatry 28 (2004) 1061– 1063D-97080

Contd.



- Lheureux PER, Penaloza A, Zahir S, Gris M. Science review: Carnitine in the treatment of valproic acid-induced toxicity – what is the evidence? *Critical Care* 2005; 9:431-440
- Guin DB et al. A case of non-hyperammonemic valproate-induced encephalopathy. *Neurology Asia* 2006; 11 : 135 – 137
- Agrawal A, Agrawal R. Valproate-Induced Non-Hepatic Hyperammonaemic Encephalopathy: A Rare Complication of Chronic Valproate Therapy. *Int J Clin Pediatr* 2012;1(2-3):85-87



THANK YOU..