



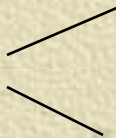
# Mastocytosis

- ✦ Mastocytosis is characterized by the accumulation of mast cells in the skin and at times in other organs of the body.
- ✦ Specific gene mutations in protooncogene *c-kit*.
- ✦ ? Autosomal dominant inheritance

# Types of Cutaneous Mastocytosis

---

✦ Urticaria pigmentosa (UP)

✦ Mastocytoma:  Solitary  
Multiple

✦ Bullous

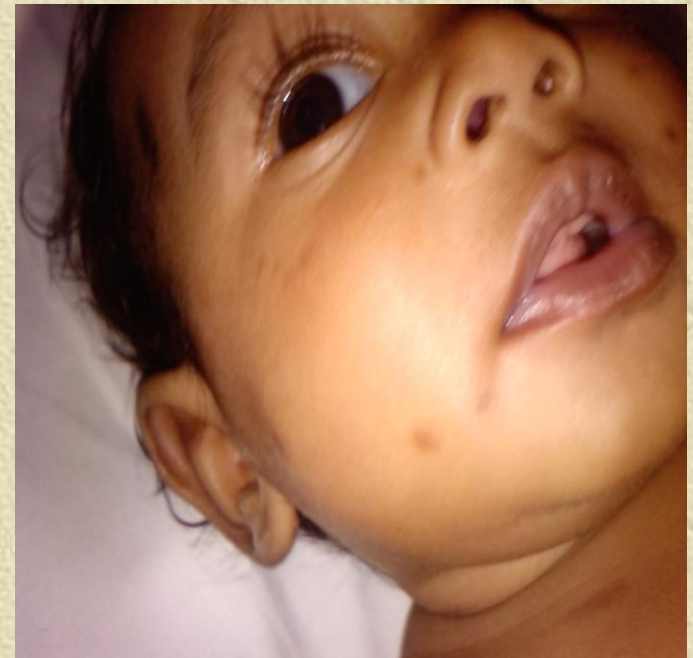✦ Diffuse cutaneous

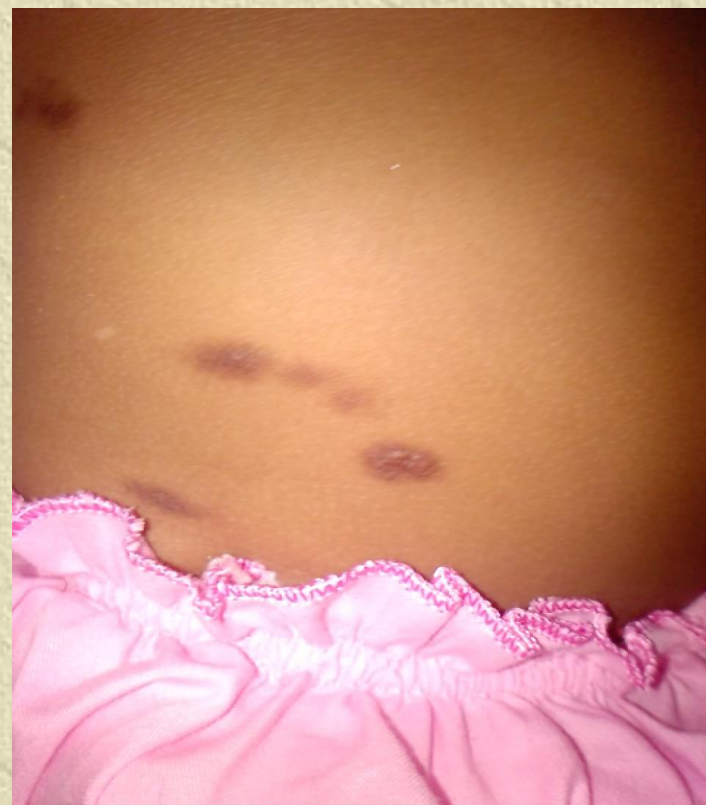
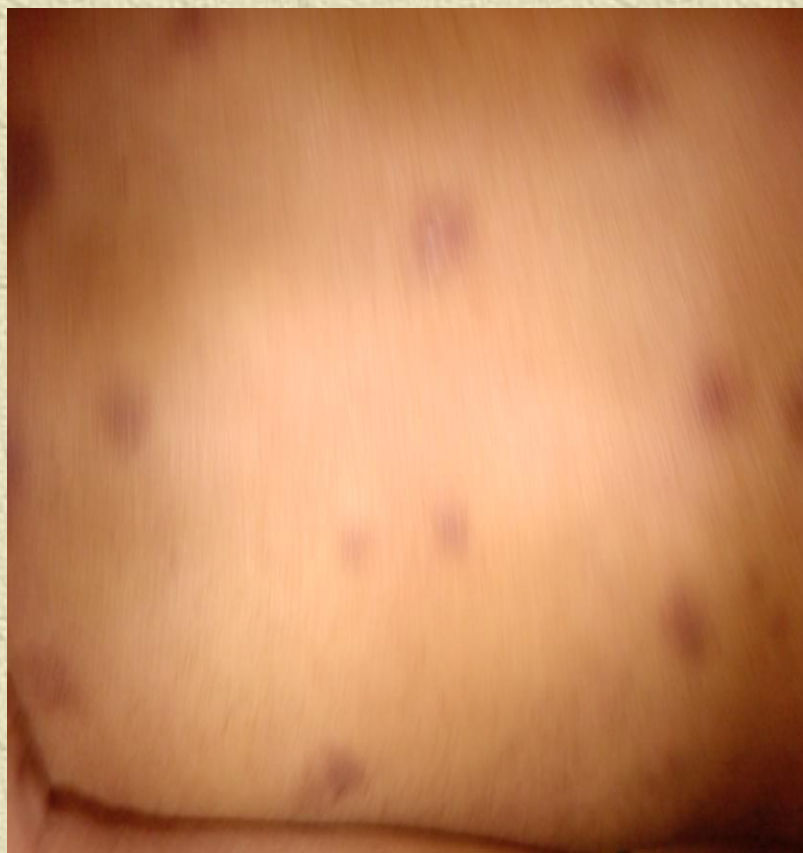✦ Telangiectasia macularis eruptive perstans

## Clinical features of UP

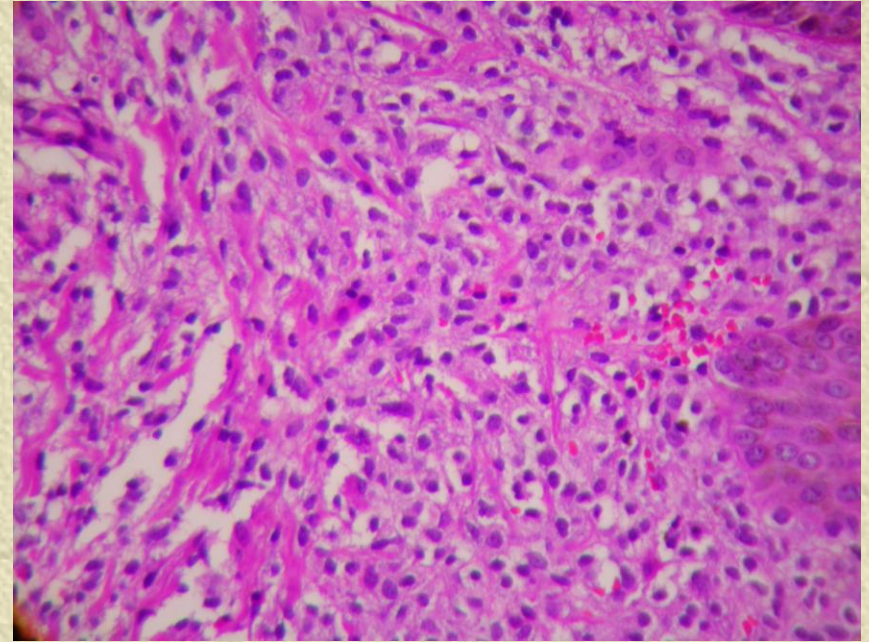
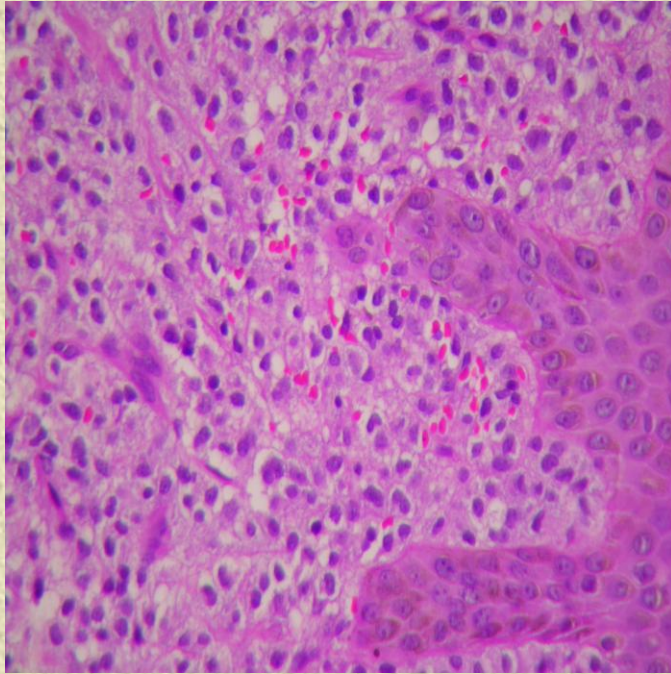
---

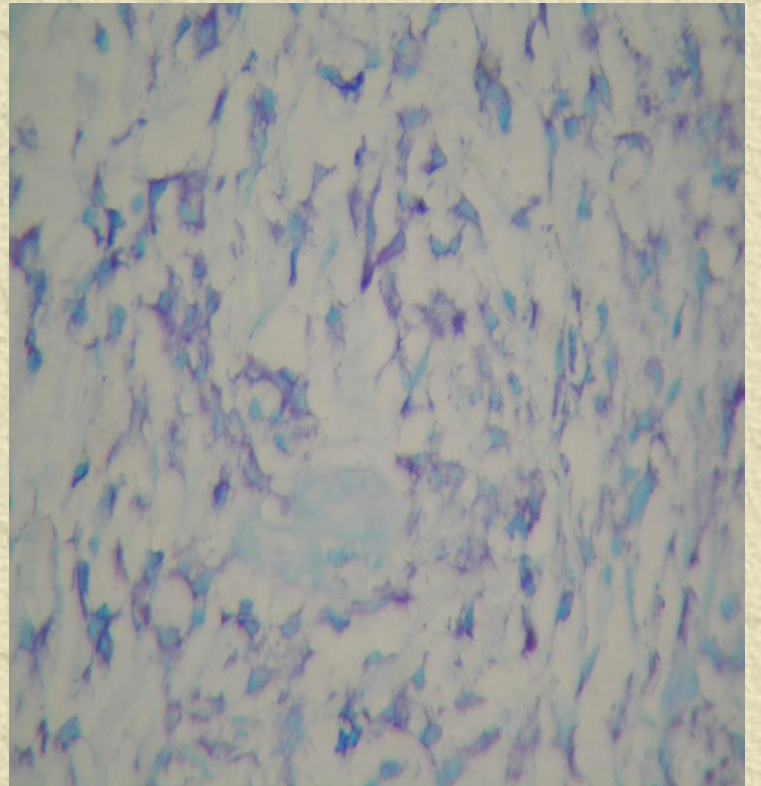
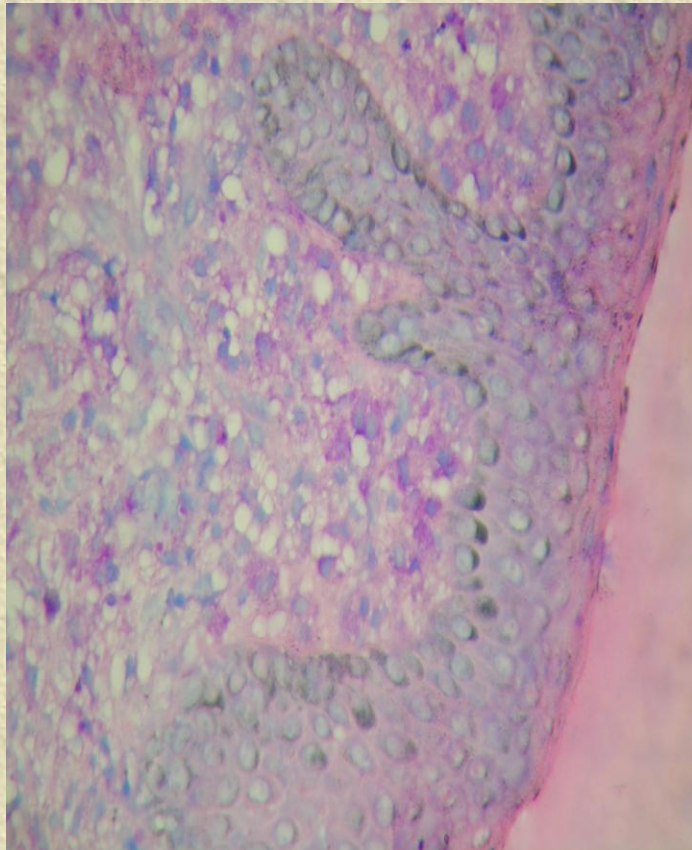

- ✦ Appears in 50% before 2 years
- ✦ Multiple brownish macules/  
papules
- ✦ Size ranges from few mm to  
few cm
- ✦ Darier's sign is positive






# Histopathology





# INVESTIGATIONS



- ✦ Serum Tryptase alpha and beta
- ✦ Urinary histamine and its metabolites
- ✦ CBC



# TREATMENT

## AVOID TRIGGERS OF MAST CELL DEGRANULATION

### ✦ Medications (systemic):

Aspirin, alcohol, morphine, codeine, dextromethorphan, NSAIDs, opiates, amphotericin B, thiamine.

### ✦ Physical exercise heart, hot baths, hot beverages, cold exposure, sunlight, stress.

### ✦ Medications (Topical):

Polymyxin B,

Medications: Sometimes used with general anaesthesia.

D-tubocurarine, scopolamine, decamethonium, gallamine, pancuronium.

# Prognosis & Treatment

---

- ✦ Most resolve in childhood
- ✦ Sedating antihistamines
- ✦ H2 antihistamines for GI symptoms
- ✦ Doxepin
- ✦ Phototherapy




---

# ACKNOWLEDGMENTS

Professor.Patrick Yesudian

Dr. Jessy Thomas



THANKS YOU