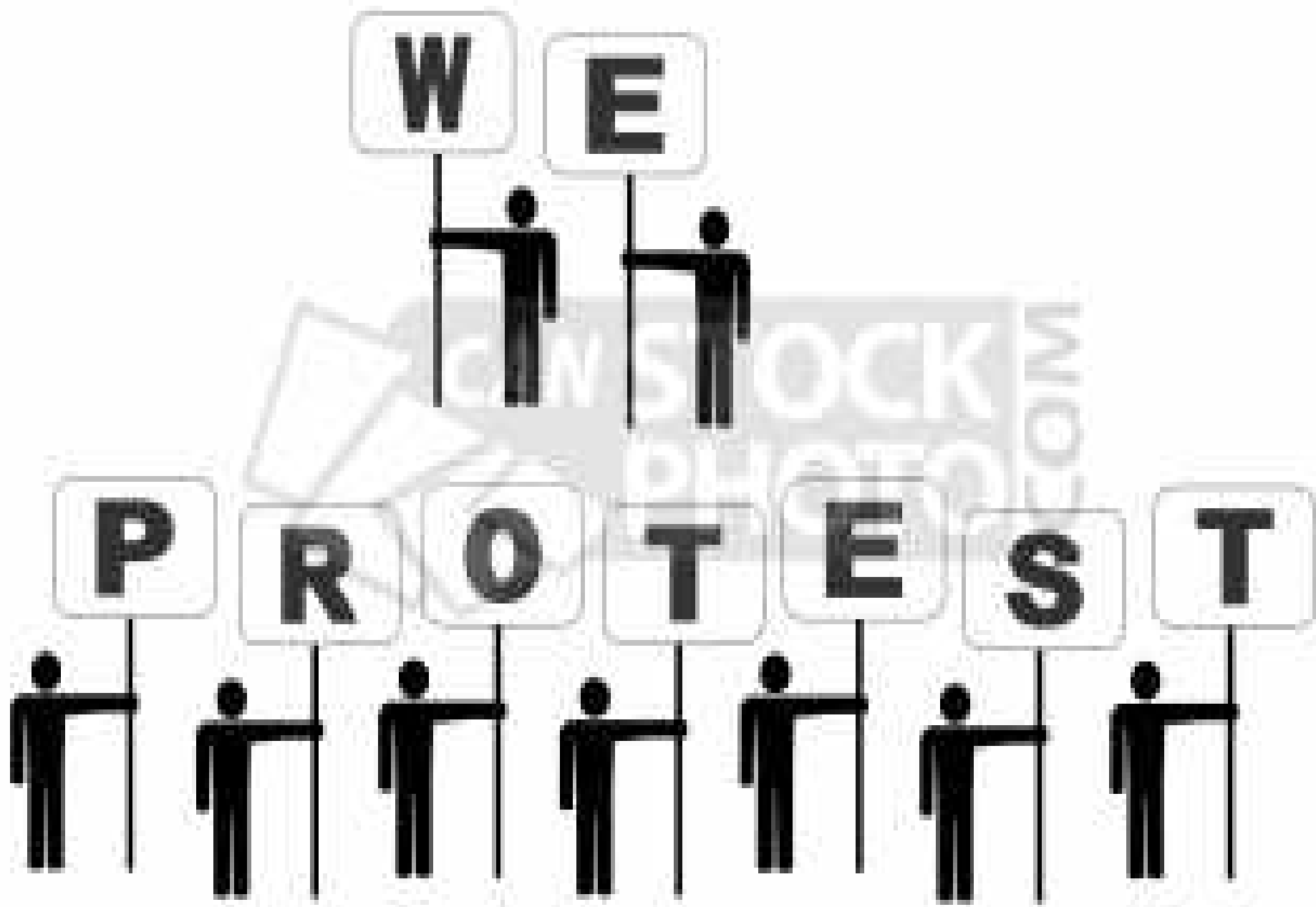



# Fire And Smoke

Dr.S.Balasubramaniam  
CHILDS Trust Hospital

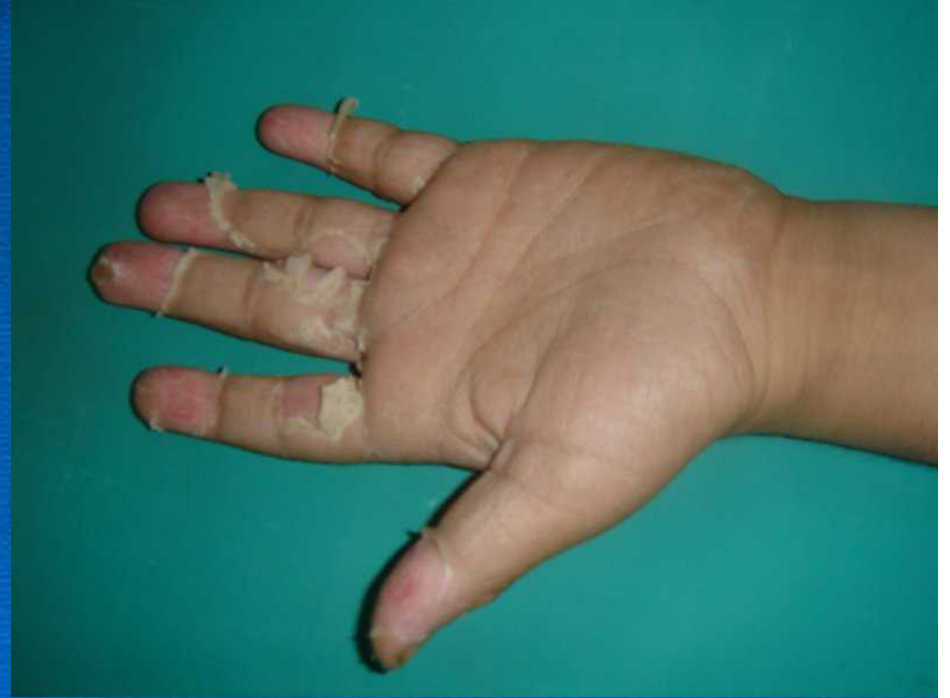
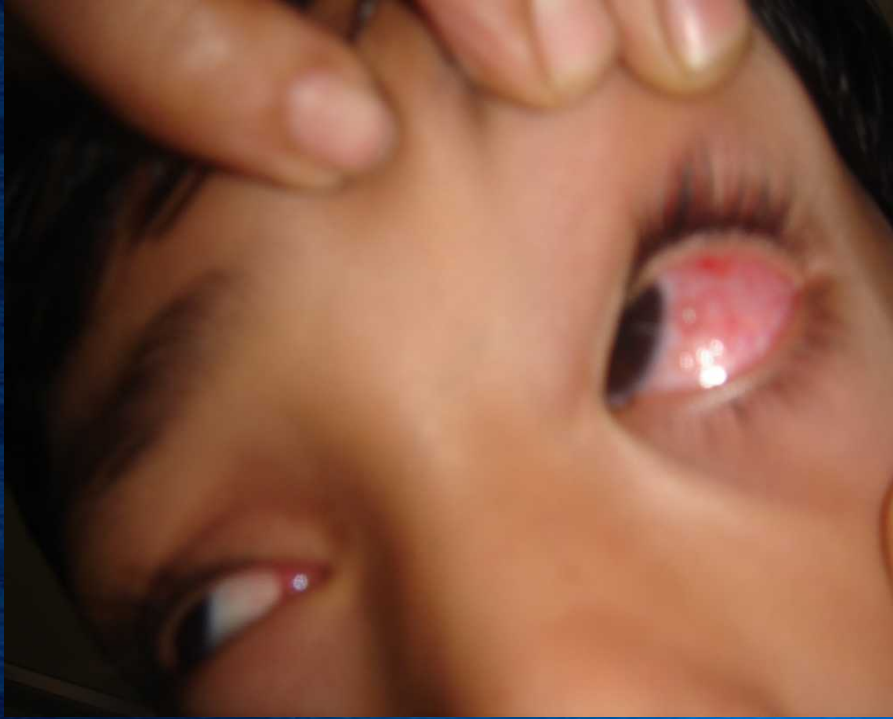
# Case History 1

- 6 year old boy with fever for 6 days
- Rash on D 1 of fever
- Chelitis on D 3
- Loose stools, abd pain on D 4
- Desquamation on D 6

# Physical Examination

- ✓ Conjunctiva Congested w/o exudate
- ✓ Strawberry Tongue
- ✓ Chelitis
- ✓ Cervical Adenopathy unilateral
- ✓ Desquamation in periungual region and elbows
- ✓ Perianal Desquamation
- ✓ Hepatomegaly



# Labs

- × TC – 18,000 with 91% neutrophils
- × ESR – 45
- × ALT – 243
- × CRP – 2.3
- × Albumin – 3
- × Urine Analysis - Normal

# Course of Events

- ◆ ECHO – Normal
- ◆ Ivlg on D 7
- ◆ Recrudescence
- ◆ Plt 2.7l to 4l
- ◆ ESR 45 to 65
- ◆ CRP 2.3 to 2.3
- ◆ Second dose Ivlg

# And THEN ....

Fever abated



Aspirin



Awaiting 6 week ECHO



# Negative CRP in Kawasaki Disease

- “... Elevated CRP is almost universal in KD...”

- AHA Position Statement CIRCULATION 2005

- A Case Report of KD in a 17 year old

- West London Med J 2009; 1 (3):49-55

- Profile of KD during the epidemic in Colorado

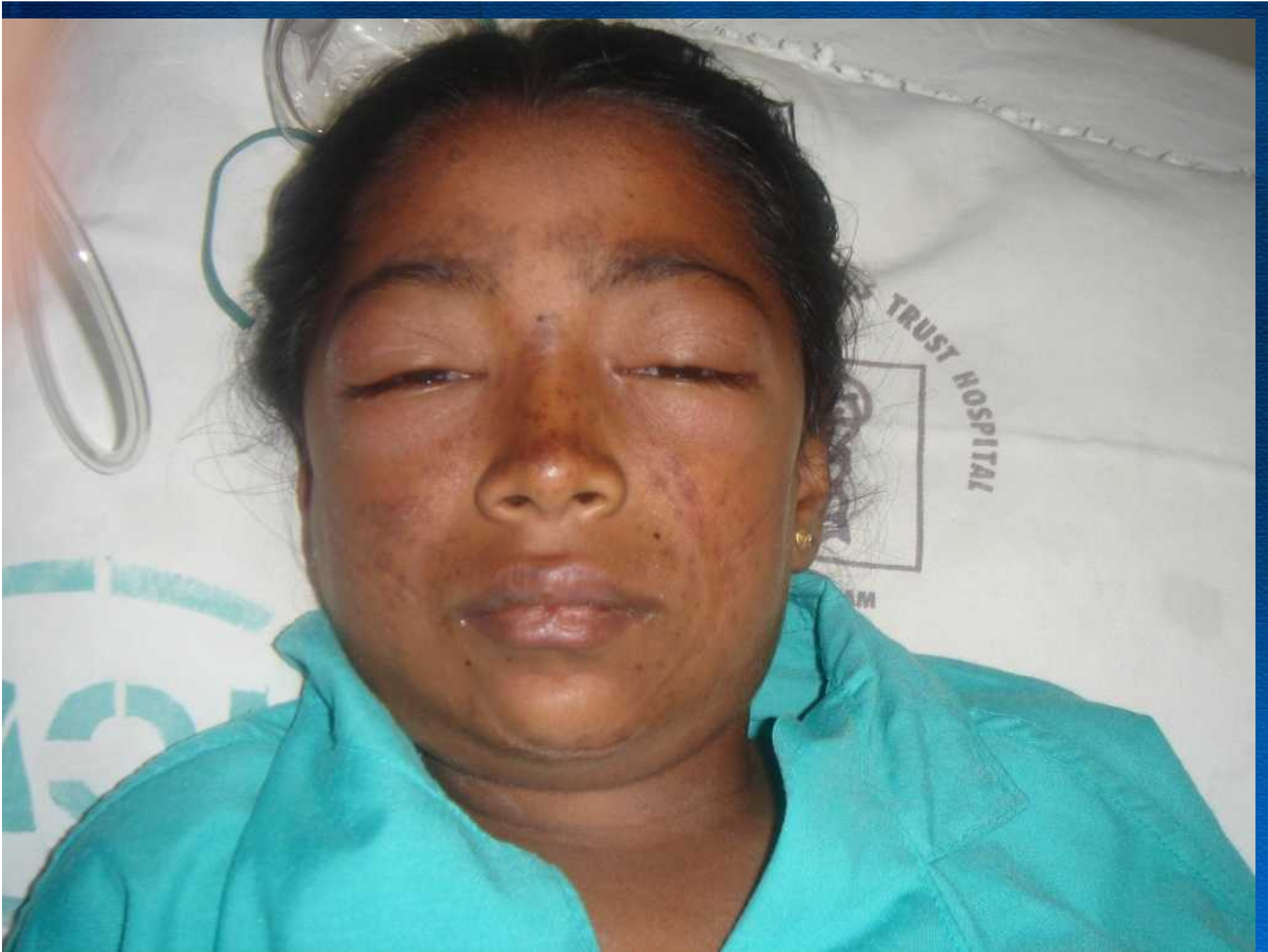- Ped Inf Dis J 2001 20 (4)

# Case History 2

- 15 year old girl with fever x 1 month
- Hypothyroid on L-Thyroxine
- Multiple Antibiotics
- Spleen Tipped
- Plt – 1.3 L & TC - 4000
- CRP: -ve, ESR – 11. Cultures , WIDAL negative
- X-Ray : Normal
- No fever
- Sigh of relief and discharge

# Two Weeks Later!!!

- ✓ Arthralgia
- ✓ Rash over the face
- ✓ ESR – 25 but CRP : negative
- ✓ Thrombocytopenia 70,000
- ✓ ANA ++++ Speckled
- ✓ C3 Low
- ✓ dsDNA strongly positive



# CRP in SLE

- Consumption of CRP by immune complexes

- J Lab Clin Med 1990; 115 : 332-8

- Genetic Factors

- J Exp Med 1982; 156 : 1268-73

- Role in prevention of Auto- Immunity

- Nat Med 5: 694-7

- Adv Imm 34: 141-212

# Case History 3

- 7 year old boy
- Fever, throat pain, difficulty in swallowing x 3 days
- Change in voice
- Puffy face
- Chelitis
- Adenitis
- Exudative tonsillitis

# Labs

- ✓ TC – 13200 with Lymphocyte Predominance
- ✓ CRP – 65
- ✓ Throat Swab – Negative
- ✓ EBV VCA Ig M – Negative
- ✓ Adeno Viral PCR - Positive

# CRP for predicting SBI


- Not bad predictor of SBI
- Serial Values than single value
- Uncomplicated viral infections like adeno, CMV, Mumps, Measles, Varicella

- Ped Inf Dis J 1997; 16 :135

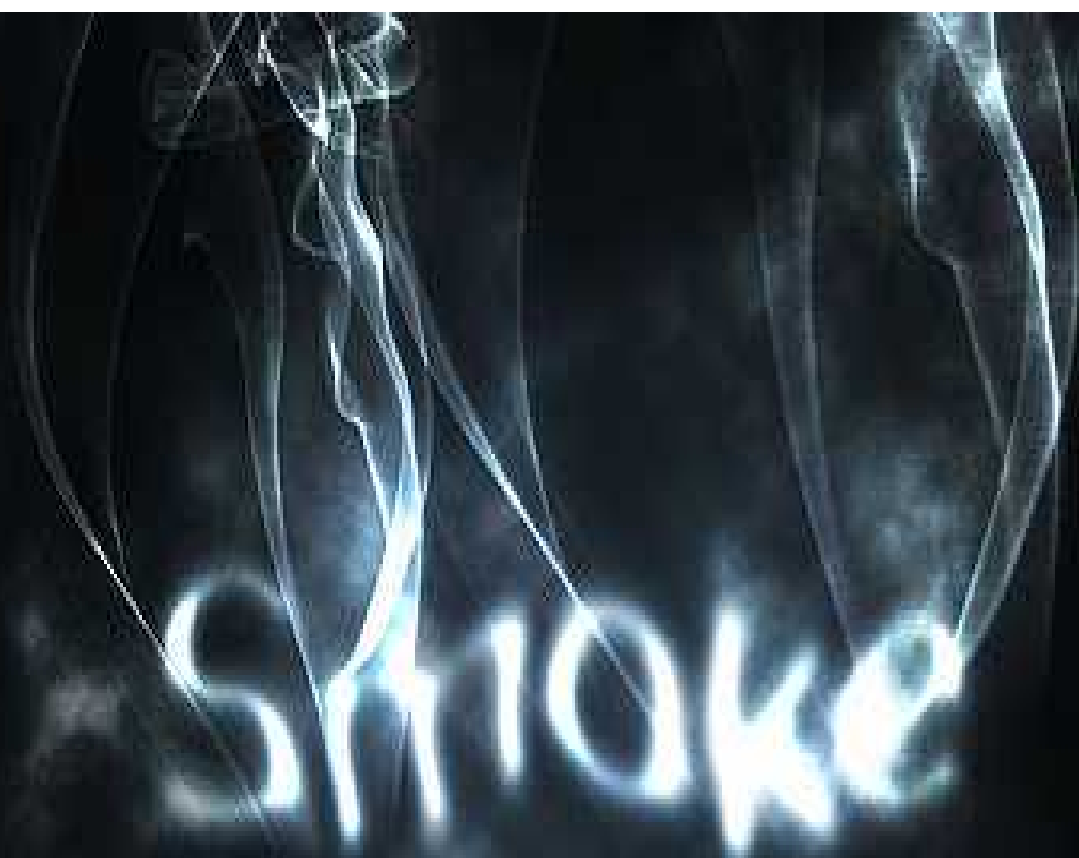- Serum CRP in children with adeno viral infection

- Swiss Med Weekly 2002





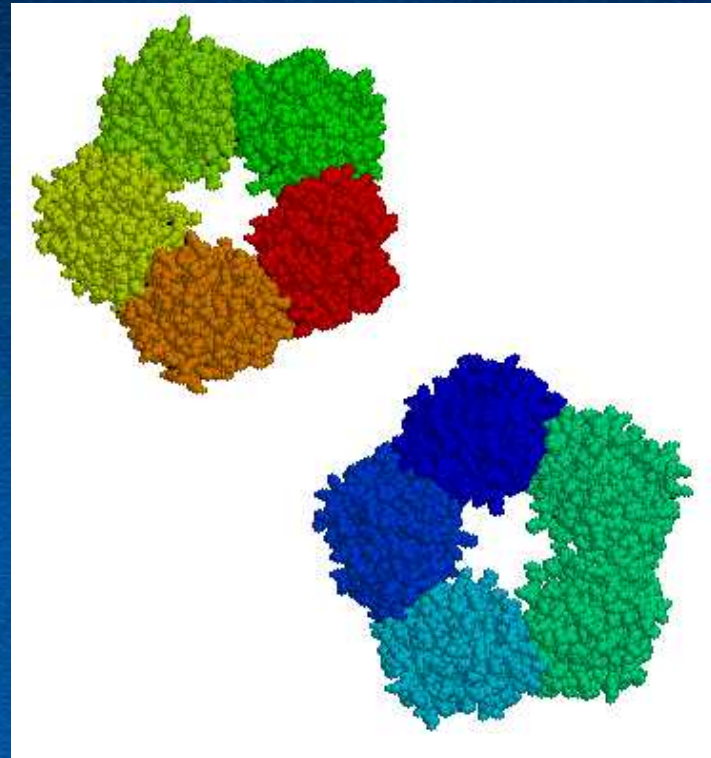
**"At last we've reached a consensus!  
This meeting is boring!"**



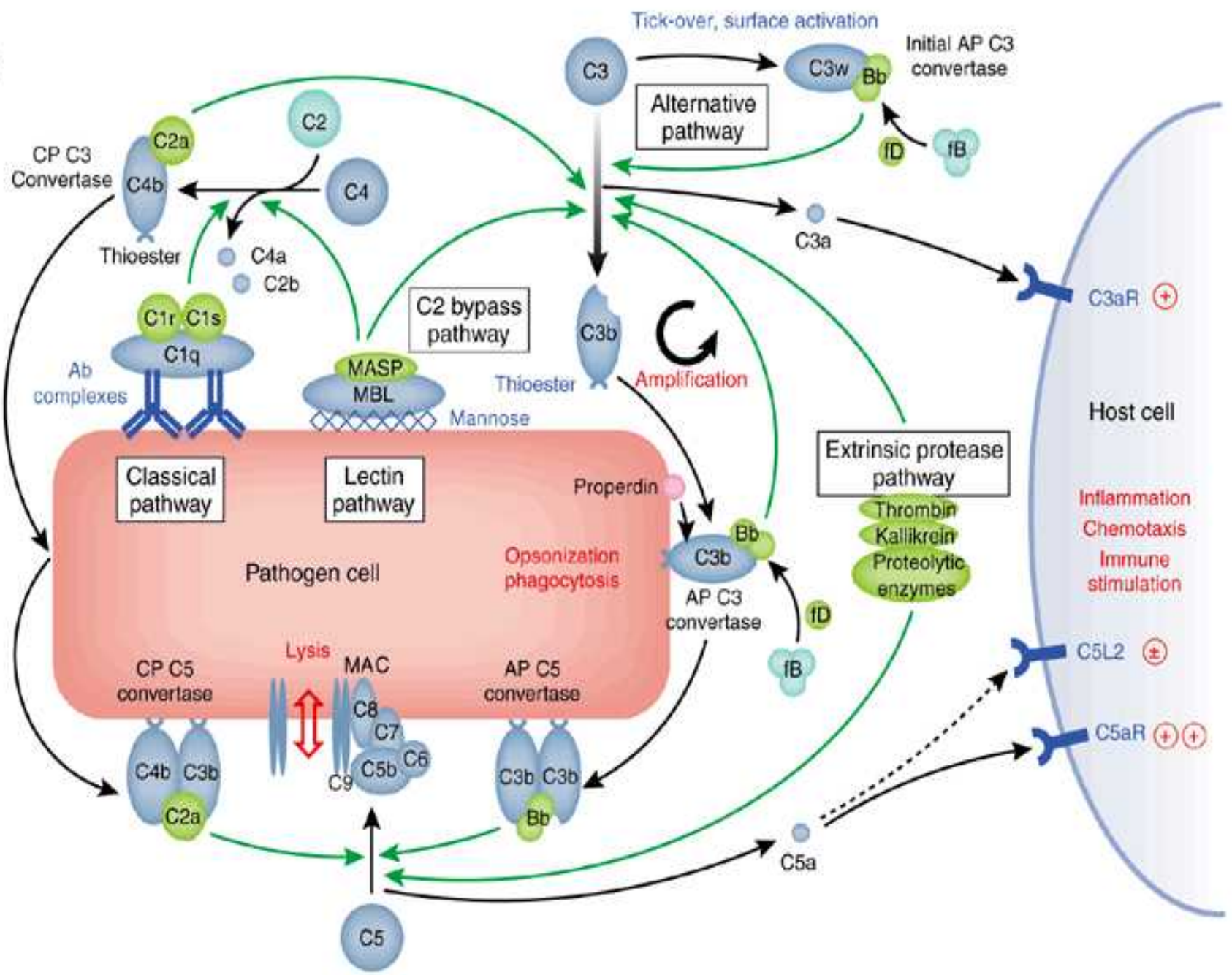
# The C – Reactive Protein


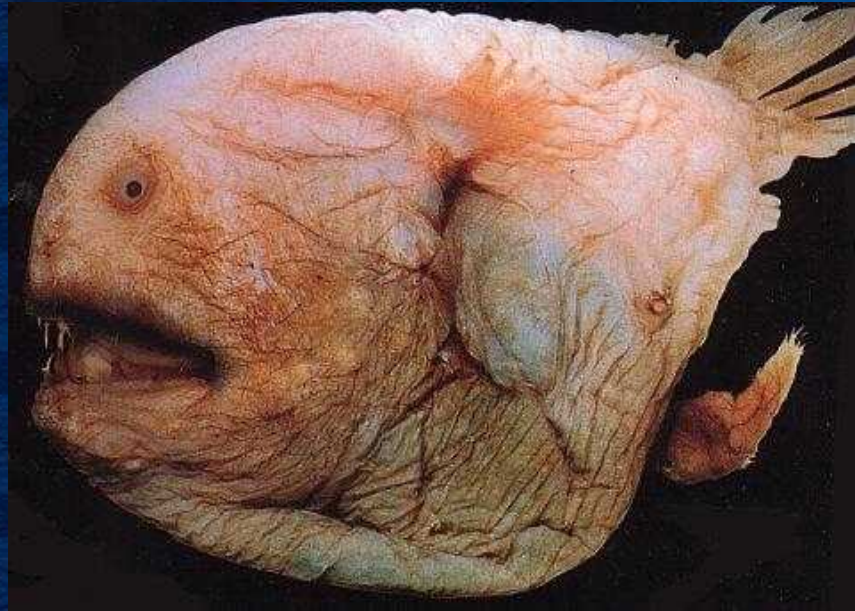
# CRP

- Pentameric Molecule
- Acute Phase Reactant
- IL-6 induced
- Opsonization and classical complement pathway
- Physiological and pathological role



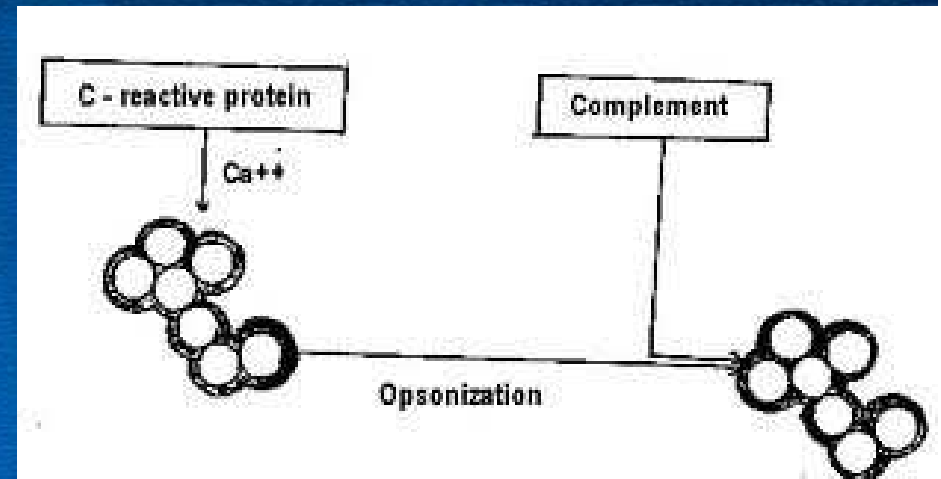
a





# Newer Roles for CRP

- ✘ Hyperlipidemia and CRP
- ✘ Protective role in Auto-Immunity
- ✘ Gene polymorphisms in CRP



*the* SCUT MONKEY  
POCKET REFERENCE



Clinician's  
Pocket  
Reference



Thank You

**SMOKE WITHOUT FIRE**  
BRIGHT EYES & M. WARD

