



UNUSUAL PRESENTATION OF TUBERCULOSIS

Dr. Janani Sankar's unit
KKCTH

HISTORY

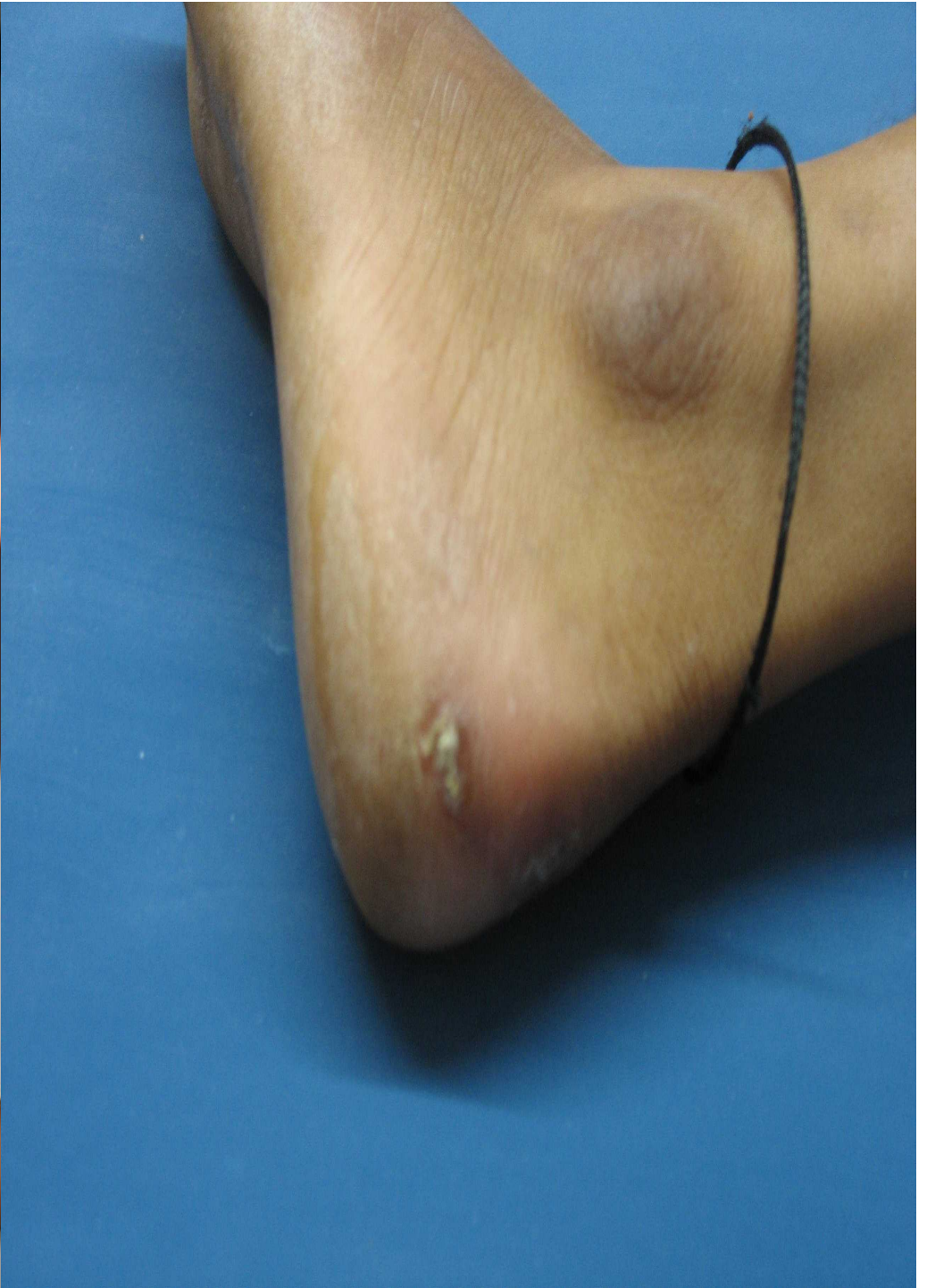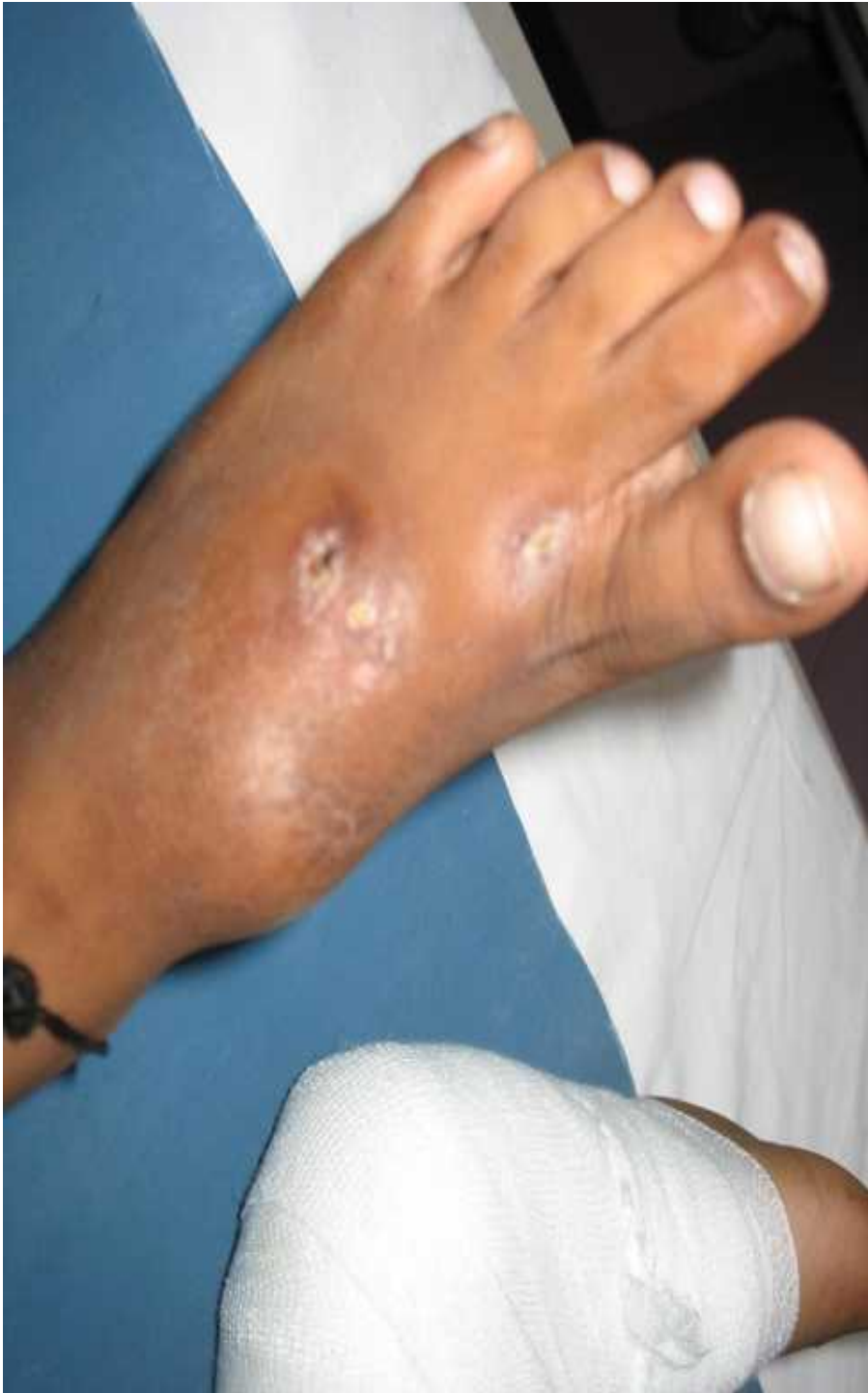- 9yr, M,
- c/o nodular skin lesions with discharging sinus, over both legs for the past 6months.
- h/o pain right hip with limping gait.
- h/o preceding trauma – fall from bicycle, received native treatment.
- h/o fever – on & off, weight loss+.
- Diagnosed as mycetoma foot – treated with dapsons & itraconazole – referred for further evaluation.



EXAMINATION

- Undernourished.
- Weight – 20kg (<5th centile)
- BCG scar seen.
- Bilateral inguinal lymphadenopathy.
- Soft nodular lesions with sinus over both feet.
- No organomegaly.





FIRST HOSPITALISATION

- Baseline investigations – ESR 63mm/hr.
- Mantoux – negative. X-ray chest, pelvis & both feet was normal.
- HIV ELISA – non reactive.

- Dermatologist opinion obtained – features suggestive of mycetoma foot.
- ?EUMYCETIC?ACTINOMYCETIC
- Orthopedician opinion – no evidence of osteomyelitis.



- Biopsy of lesion done under GA – gram stain, AFB stain, PAS stain - no organisms identified. Culture awaited.
- Skin biopsy HPE – evidence of granuloma, no caseation.
- Discharged on oral cotrimoxazole, IM Amikacin. (to cover for actinomycetoma)



READMISSION

- c/o fever, headache and vomiting for 3 days.
- Skin lesions – marginally better. Nodular lesions with healed sinus.
- o/e sensorium – normal, neck stiffness+.

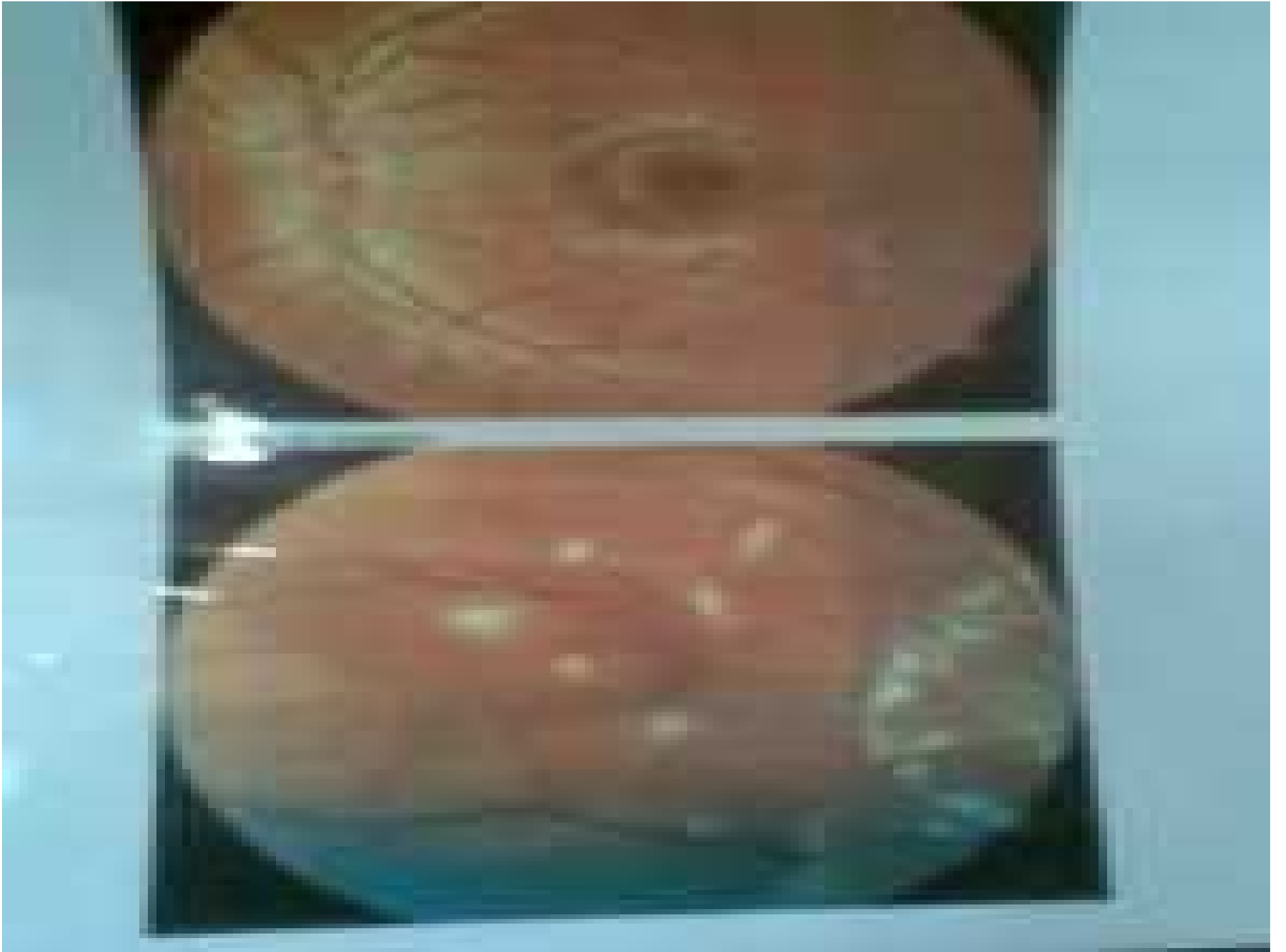
INVESTIGATIONS:

- **ESR 63mm/hr.**
- CT Brain – normal.
- **CSF analysis – sugar 30mg/dl, protein 120mg/dl, 29 WBC's, lymphocytes.**



- MRI Brain - **multiple tiny ring enhancing lesions** in cerebellum and supratentorial frontal parenchyma with mild dilatation of both lateral ventricles, MR spectroscopy showed mildly elevated lipid/lactate peak.
- Ophthalmologist opinion – Fundus examination showed **healed chorioretinal lesions.**
- QUANTIFERON – report awaited.





DIAGNOSIS

- Chronic granulomatous skin lesion
- Meningitis
- Intracranial granulomas
- Healed chorioretinal lesions

- Mantoux negative, Chest X-ray – normal.
- ?Contact history – grandmother HIV positive, was given empirical ATT.



TREATMENT

- Antituberculous with steroid treatment started.
- 2HRZE/7HR with steroid.



ON THE DAY OF DISCHARGE

- QUANTIFERON – Positive.
- Call from VRF Lab!!!!!!!
Skin biopsy AFB culture – POSITIVE FOR
MYCOBACTERIUM TUBERCULOSIS!!



DISCUSSION

Forms of cutaneous tuberculosis

- Scrofuloderma
- Tuberculosis verrucosa cutis
- Tuberculous gumma
- Lupus vulgaris
- Tuberculids
- Miliary tuberculosis of the skin
- TB cutis orificialis



DISCUSSION

- Cutaneous tuberculosis constitutes about 1.5% of all extra pulmonary tuberculosis.
- Of all the clinical types, scrofuloderma (SFD) is the most commonly encountered variant followed by lupus vulgaris (LV) and tuberculosis verrucosa cutis (TBVC).
- Cutaneous tuberculosis in children: the Indian perspective.
- Indian J Dermatol Venereol Leprol. 2010 Sep-Oct;76(5):494-503



DISCUSSION

- Underlying systemic involvement is more common in children, compared with adults.
- A thorough clinical evaluation and exhaustive investigations to pin-point associated systemic focus is advocated as the latter has an impact on the duration of treatment.
- Skin tuberculosis in children: learning from India
Dermatol Clin. 2008 Apr;26(2):285-94.
- Cutaneous tuberculosis in Indian children: the importance of screening for involvement of internal organs
J Eur Acad Dermatol Venereol. 2004 Sep;18(5):546-51.
- Cutaneous tuberculosis in children: the Indian perspective.
Indian J Dermatol Venereol Leprol. 2010 Sep-Oct;76(5):494-503.



REVIEW OF LITERATURE:

- 63 children out of a total of 199 patients seen with cutaneous tuberculosis
- Tuberculous infection either in the lungs or the bones in 8 children.
- HIV test done in five patients with widespread lesions was negative.

- **A Study of Cutaneous Tuberculosis in Children-** Ramesh, V et al
Pediatric Dermatology. 16(4),264-69:1999



MESSAGE

- Uncommon presentation of a common condition is more common, than a common presentation of an uncommon disease.
- The importance of skin biopsy culture.

