

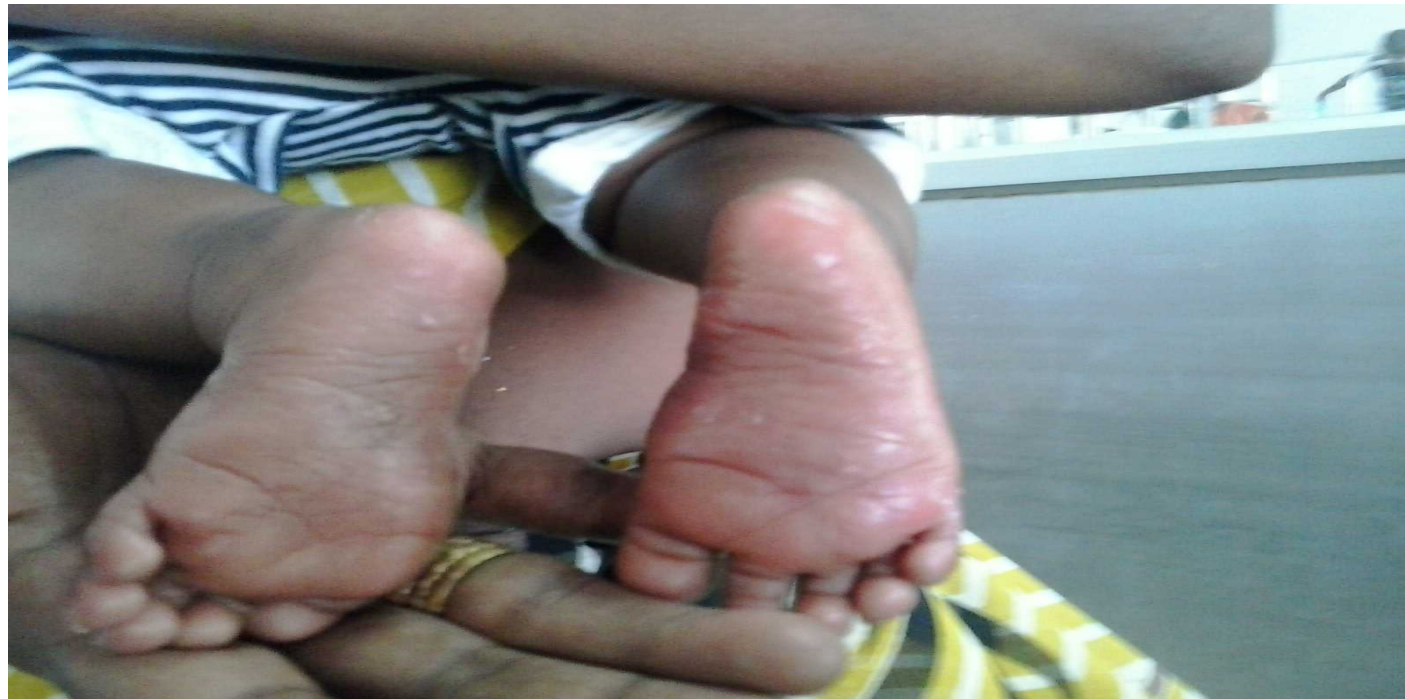

A FORGOTTEN DISEASE


Dr V.M.Baskaran


M4 unit

ICH&HC

- 5 months old girl child 2nd born of non consanguineous marriage brought by their parents with complaints of
- Excessive cry for 1 month duration ,cry increased when handling the baby.
- Swelling in the right elbow and left foot for 1 month duration, insidious onset non progressive swelling associated with decreased movements
- Skin lesions with desquamation over both soles 1 month duration

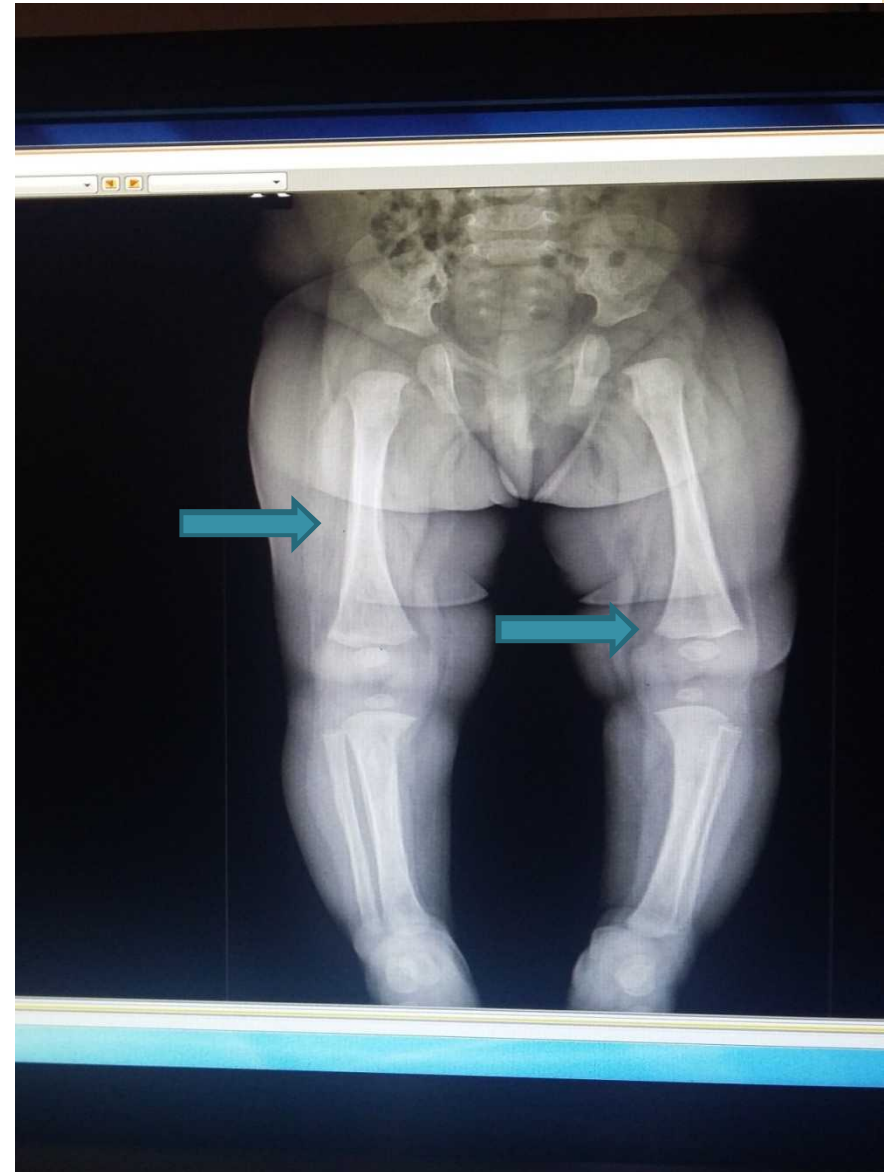

- 
- Past history: h/o similar swelling in left elbow and left foot lasted for 1 month & resolved spontaneously
 - Antenatal history: VCTC/VDRL testing not done, No h/o previous abortion
 - Birth history: FTND BW 2.5kg. Uneventful
 - Development history: No h/o developmental delay
 - Immunised upto age
 - Family h/o: elder sibling 3yrs alive & healthy

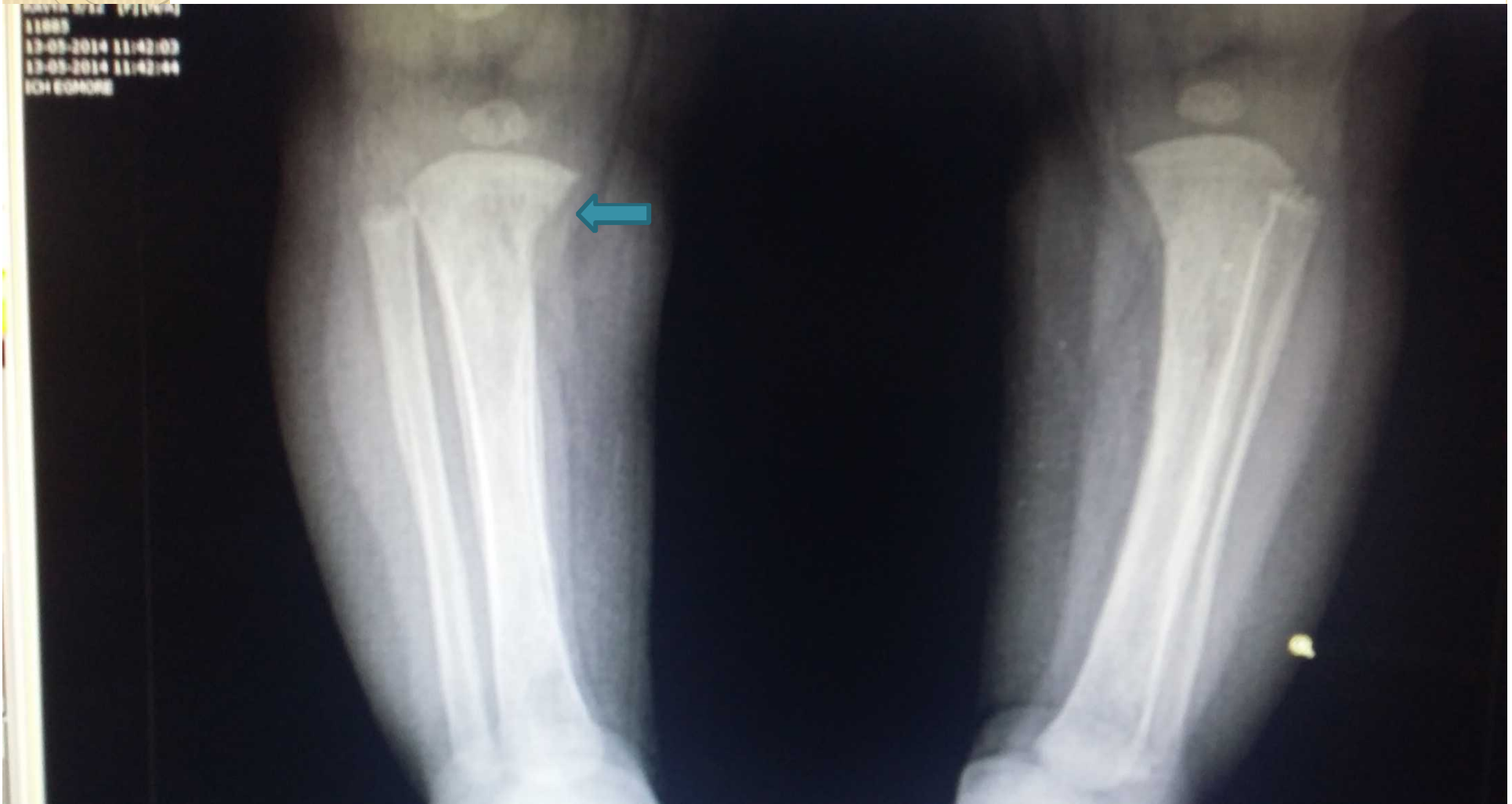- 
- Examination: Irritable cry when handling the baby
 - Maculopapular skin lesions with desquamation present over both soles
 - Vitals normal
 - CVS/RS/Abdomen/CNS- NAD
 - CBC/Biochemical parameters/Sepsis work up/CXR/USG Abdomen- Normal
 - TB screening- negative

Skeletal X ray study

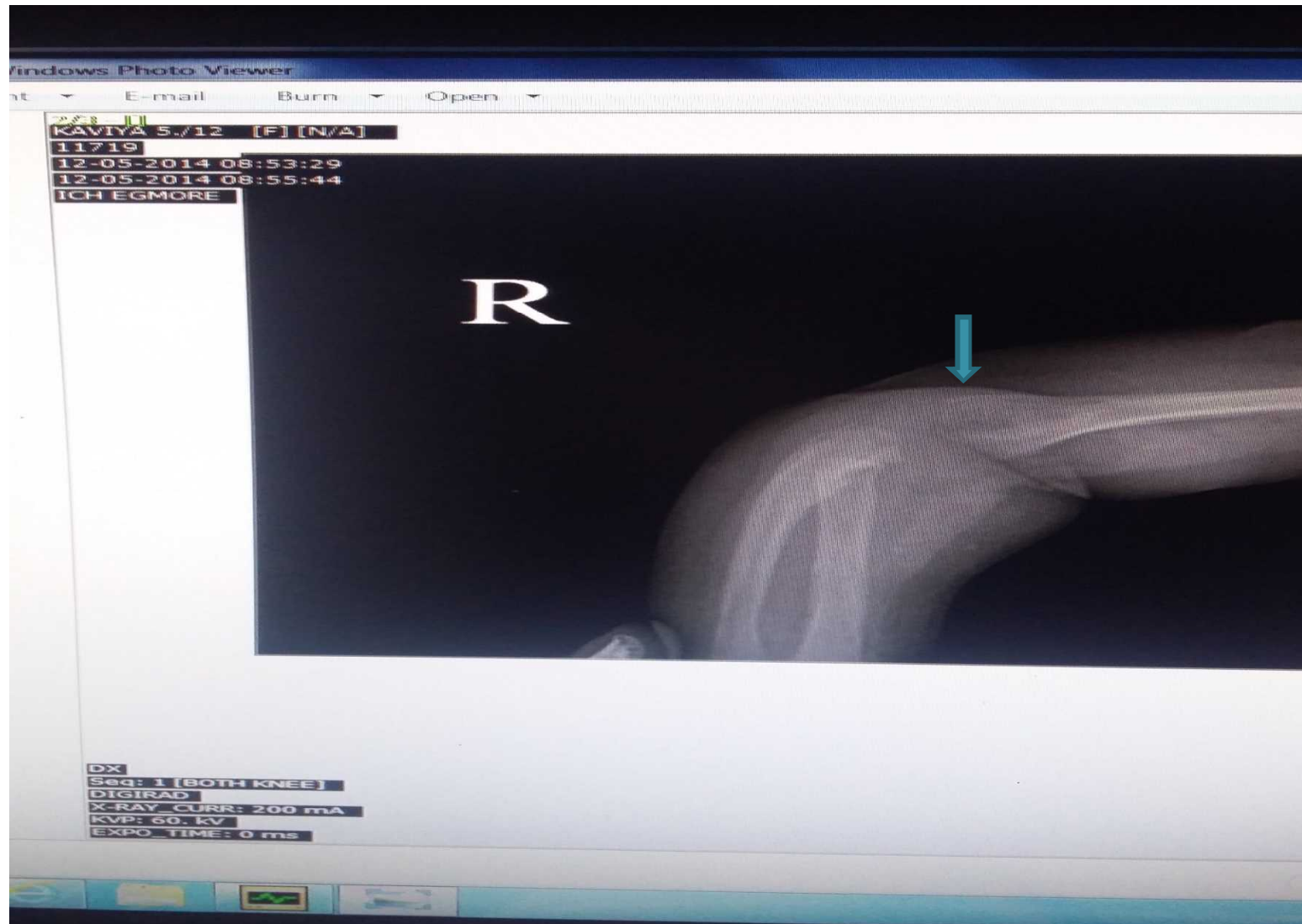- Generalized periosteitis & metaphysitis of long bones (Humerus, Femur, Tibia)




Wimberger's line- Metaphyseal demineralisation of medial aspect of proximal tibia



Metaphysitis (moth eaten appearance) – lytic bone lesion seen



- 
- VDRL - 1:64 Dilutions positive
 - TPHA - Positive
 - HIV - Non reactive
 - H/O Genital ulcer for father before conception
 - VDRL & TPHA positive for both mother and father
 - Hence diagnosis of congenital syphilis made and confirmed
 - Child and parents were treated accordingly and was discharged



THANK YOU